

Combining Tissue-sparing MicroPulse™ Laser Therapy and Anti-VEGF Medication Produces Unprecedented Results in Radiation Retinopathy



Timothy G. Murray, MD, MBA, FACS, FAAO, is the founder and director of Murray Ocular Oncology and Retina in Coral Gables, Fla. An internationally recognized eye cancer specialist, Dr. Murray has more than 20 years of experience in research, teaching and clinical care.

MicroPulse is a laser energy delivery modality that enables fine control of the thermal effects of photocoagulation. With MicroPulse technology, a continuous-wave laser beam is broken into a train of tiny, repetitive, low-energy pulses that are separated by brief rest periods. This allows tissue to cool between laser pulses, which minimizes or prevents tissue damage. MicroPulse Laser Therapy (MPLT) has been primarily used in the treatment of glaucoma^{1,2} and retinal vascular diseases such as diabetes³⁻⁵ and vein occlusion.^{6,7} Recently, I became interested in exploring whether this tissue-sparing strategy could play a role in my practice.

I have been evaluating MPLT in conjunction with anti-VEGF therapy for patients who have developed radiation retinopathy. This condition is a major cause of vision loss in patients who have undergone radiation treatment for an ocular malignancy. Furthermore, even though SDOCT shows us that approximately 85% of patients develop radiation retinopathy by 9 months after radiation treatment, and the risk increases with time, no standard-of-care treatment strategy has emerged, though recent studies have suggested the benefit of early recognition and targeted use of intravitreal anti-VEGF as evolving treatment strategies.⁸ While intravitreal steroids and anti-VEGF agents can improve anatomic and visual outcomes in these patients, persistent radiation retinopathy remains all too common.

My initial aim in studying MPLT for radiation retinopathy in my practice was to determine whether it might enable me to either spare patients the need for further anti-VEGF treatment, or at least reduce the number of injections they typically require. My results have far exceeded my expectations, as the following case illustrates.

PATIENT PRESENTATION

A 50-year-old woman was treated for posterior uveal

melanoma with COMS configured 125-Iodine plaque radiotherapy in March 2009. In July 2012, she was diagnosed with Grade V radiation retinopathy. Although radiotherapy produced excellent results in local tumor control, SDOCT showed severe intraretinal cystic edema, and her visual acuity had decreased to 20/100.

MPLT TREATMENT

It is important to understand that during subthreshold MPLT, there are no visible effects on the retinal tissue during treatment, and no “burns” can be seen at any time post treatment. This is such a departure from what we are accustomed to with all other forms of photocoagulation, it initially concerned me. I wondered how I would know exactly what was happening, and how and where I was treating. Now that I have experience with MicroPulse, I am much less concerned about this than I am with the anatomical and visual response of these treatments.

I use the IRIDEX IQ 532™ laser to perform MPLT. I first use the laser in its continuous-wave emission mode to conduct a test burn to determine the power for the MicroPulse treatment. Using a 100 μm spot and 100 ms duration, I perform the test burn away from any visually significant structure in an area of the retina with pigmentation and thickness comparable to where I plan to treat. I look for moderate whitening of the retina as my clinical endpoint, not mild or intense, about half of what used to be done with ETDRS intense burns. I do this in every case because pigmentation tends to vary between patients. In this case, I achieved moderate

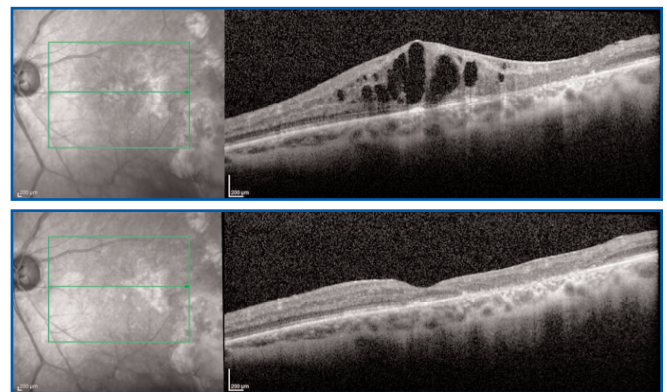


Figure 1. Before and after one MPLT treatment in conjunction with anti-VEGF therapy for radiation retinopathy. In this patient, foveal contour was restored and visual acuity improved from 20/100 to 20/25. No further treatment has been required.

whitening using 80 mW.

For MicroPulse treatment, I switched the laser to its MicroPulse emission mode and used a 5% duty cycle. I doubled the power determined from the test burn (in this case from 80 mW to 160 mW). I used the same 100 µm spot size and doubled the pulse duration (from 100 ms to 200 ms) using a repetitive pulse mode to deliver 244 micropulses, as described in Table 1. When I am delivering MicroPulse treatment for radiation retinopathy, I identify the tumor margin and place a sector of pulses that goes in a compacting style from the margin directly toward the foveal avascular zone (FAZ). I am not concerned about treating through the FAZ. However, this case was among my first, so I did not treat beyond the FAZ margin. The patient, who had been nervous about what the treatment would feel like, reported no pain.

TREATMENT OUTCOMES

As explained previously, I treated this patient with anti-VEGF injections in addition to MPLT, and the response was something I had never before seen with standard anti-VEGF therapy in patients with radiation retinopathy. Three months after MPLT, SDOCT showed that the foveal contour had been restored and the cystic edema had resolved. The patient’s visual acuity improved from 20/100 to 20/25, and she did not require retreatment (Figure 1).

MPLT AS FIRST-LINE TREATMENT?

Prior to my current evaluation of MPLT in my practice, I did not have much experience with it. However, I can say now that it has been one of the easiest treatments I have ever adopted. Because the therapeutic window for radiation retinopathy is so large, I had no anxiety about MPLT even in treating my first patient. From my very first case, this technology has been a game-changer for me. I compare it to performing my first macular hole surgery and seeing firsthand how well it works.

TABLE 1. TREATMENT PARAMETERS

IRIDEX IQ 532™ for radiation retinopathy in patients with good local tumor control, primary maculopathy on SDOCT and documented decline in visual acuity

- Wavelength: 532 nm
- Spot size on slit lamp adapter: 100 µm
- Contact lens: Haag-Streit 901 Macula Lens (as the pathology was posteriorly located)
- Power: 160 mW (based on 2x the power determined from a continuous-wave test burn)
- Exposure duration: 200 ms
- Duty cycle: 5%
- MicroPulse delivery: 244 micropulses using repetitive pulse mode

MPLT is an exciting avenue for new treatment in radiation retinopathy, an area where there is currently no existing standard of care. It may give us the ability to alter the micro environment for these patients without inducing thermal destruction of retinal tissue and decreasing or eliminating the need for additional therapy. Based on my experience so far, I am comfortable enough to use the treatment for any radiation retinopathy patient who presents with visual acuity between 20/40 and 20/200, and primary maculopathy on SDOCT.

To date, I have been coupling MPLT with anti-VEGF treatment. However, the results have been so favorable, I am considering treating with MPLT first, holding anti-VEGF treatment, but coming back to anti-VEGF if I am not satisfied with the response at 3 months. I look forward to further evaluation of MPLT for radiation retinopathy, including longer-term follow-up and learning whether it has an impact on local tumor control. ■



For additional information on this case report, see MicroPulse panel discussion. <http://bit.ly/UfCWwp>

REFERENCES

1. Fea AM, et al. Micropulse Diode Laser Trabeculoplasty (MDLT): A Phase II Clinical Study with 12 Months Follow-Up. *Clin Ophthalmol* 2008; 2(2):247-252.
2. Samples JR, et al. Laser Trabeculoplasty for Open-Angle Glaucoma: A Report by the American Academy of Ophthalmology. *Ophthalmology* 2011;118(11):2296-302.
3. Vujosevic S, et al. Microperimetry and Fundus Autofluorescence in Diabetic Macular Edema: Subthreshold Micropulse Diode Laser Versus Modified Early Treatment Diabetic Retinopathy Study Laser Photocoagulation. *Retina* 2010;30(6):908-916.
4. Lavinsky D, et al. Randomized Clinical Trial Evaluating mETDRS Versus Normal or High-Density Micropulse Photocoagulation for Diabetic Macular Edema. *Invest Ophthalmol Vis Sci* 2011;52(7):314-323.
5. Luttrull JK, et al. Long-Term Safety, High-Resolution Imaging, and Tissue Temperature Modeling of Subvisible Diode Micropulse Photocoagulation for Retinovascular Macular Edema. *Retina* 2012;32(2):375-386.
6. Parodi MB, et al. Subthreshold Grid Laser Treatment of Macular Edema Secondary to Branch Retinal Vein Occlusion with Micropulse Infrared (810 Nanometer) Diode Laser. *Ophthalmology* 2006;113(12):2237-2242.
7. Luttrull JK. Laser for BRVO: History and Current Practice. *Retina Today* 2011;May/June:74-76.
8. Shah NV, Houston SK, Markoe AM, Feuer W, Murray TG. Early SD-OCT Diagnosis Followed by Prompt Treatment of Radiation Maculopathy Using Intravitreal Bevacizumab Maintains Functional Visual Acuity. *Clin Ophthalmol* 2012;6:1739-1748.

Treatment techniques and opinions presented in this case report are those of the author. IRIDEX assumes no responsibility for patient treatment and outcome. IRIDEX, IRIDEX logo are registered trademarks, and MicroPulse is a trademark of IRIDEX Corporation.